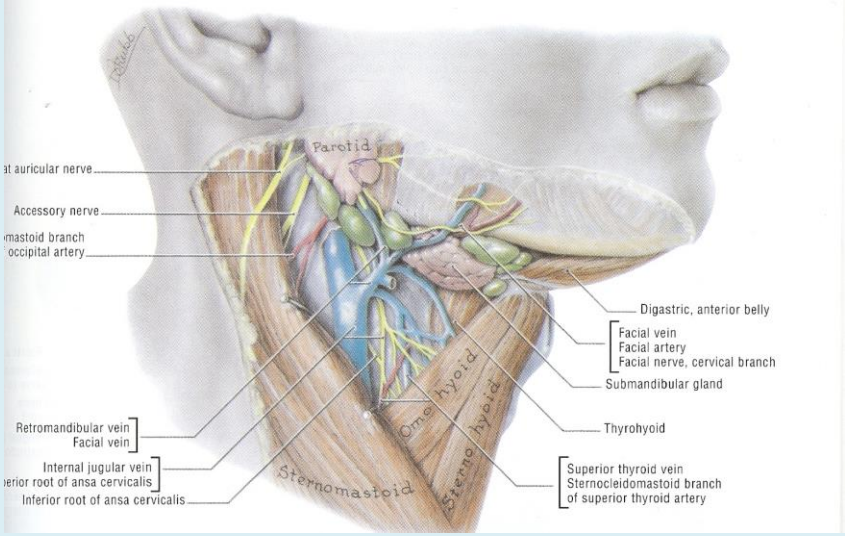

Halsweichteile, Lymphknoten

Moudon 10/23

Thomas Chlibec

interdisziplinäres Ultraschallzentrum Rorschach

www.swisssono.ch

SCAN ME

Halsweichteile, Lymphknoten

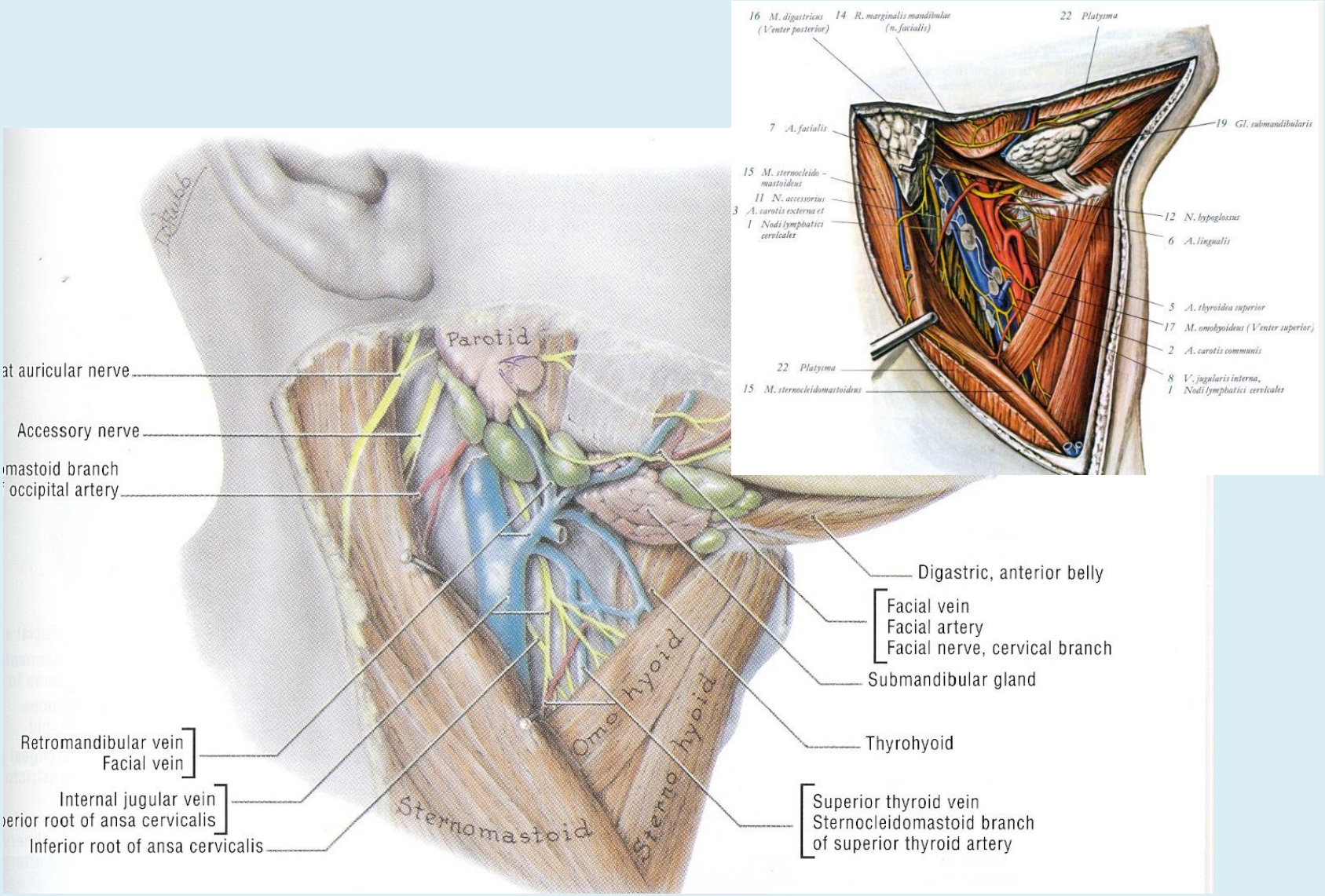

Halsweichteile, Lymphknoten

Vessels
Lymphnodes
Salivary glands
Thyroid
S.c. Tissue and muscles
Tumor??? Thickening???

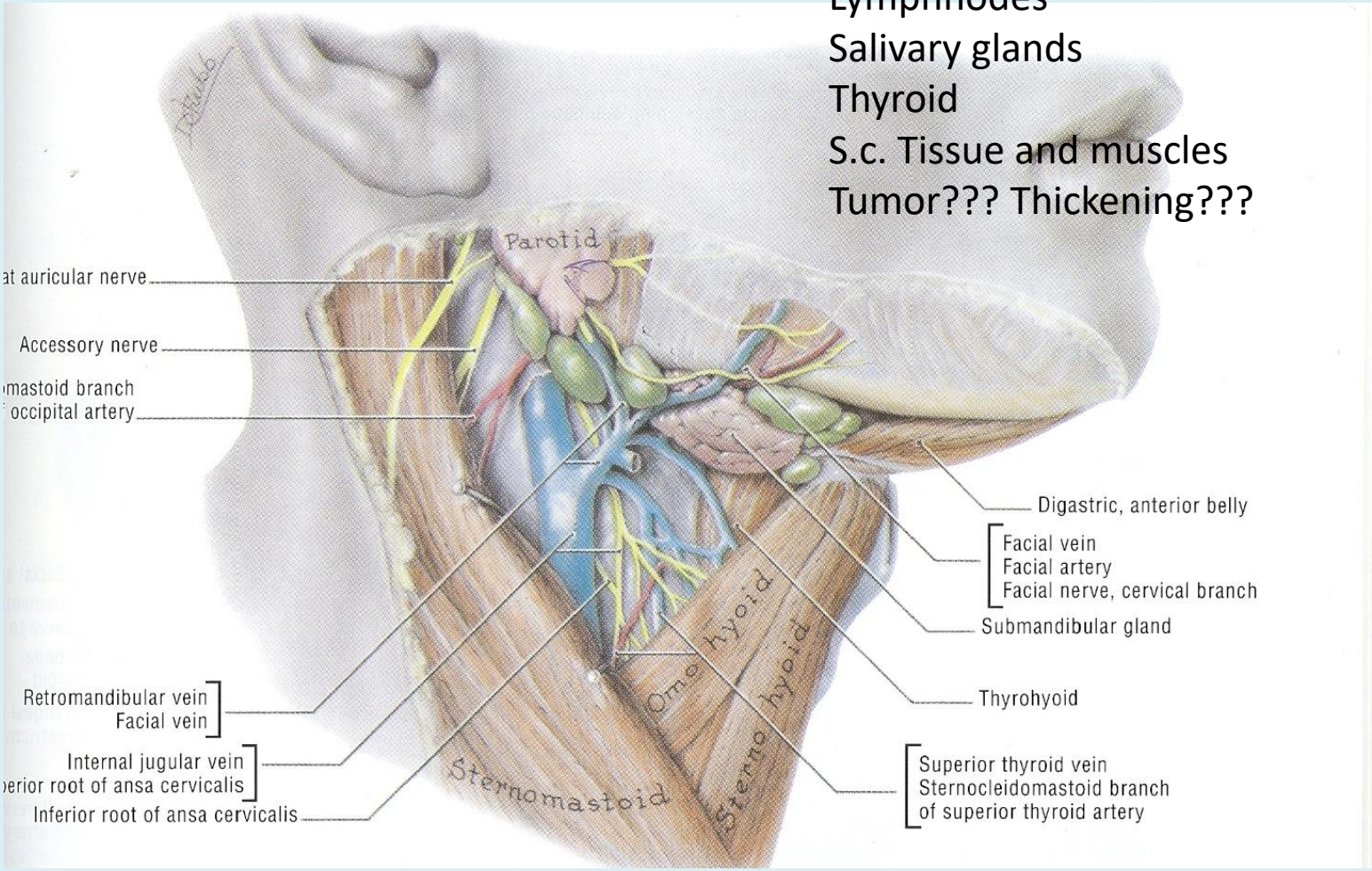

Sonoanatomie Hals I

Sonoanatomie li Halsseite

Normalbefund

Halsweichteile Untersuchungsablauf

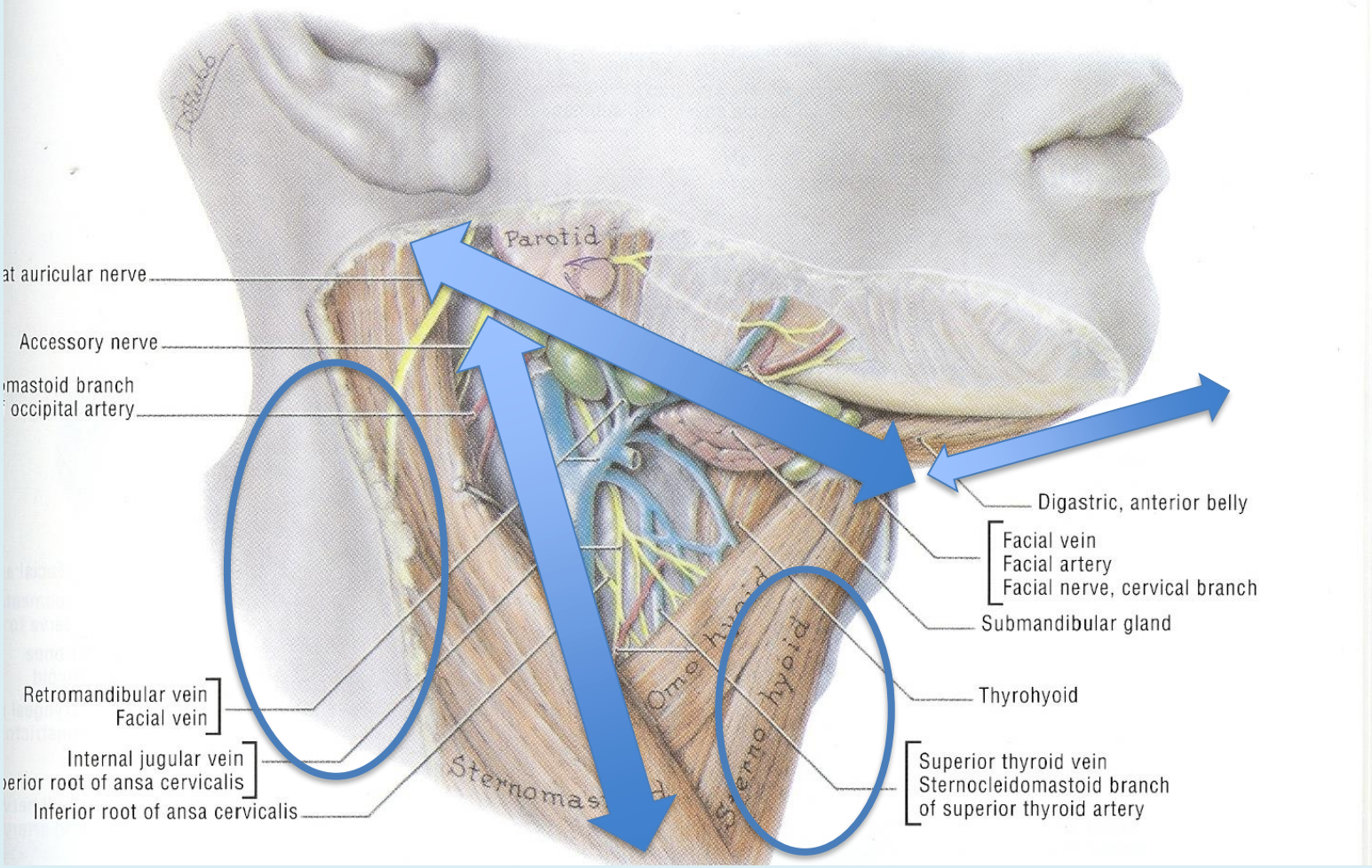

Halsweichteile, Lymphknoten

Vessels
Lymphnodes
Salivary glands
Thyroid
S.c. Tissue and muscles
Tumor??? Thickening???

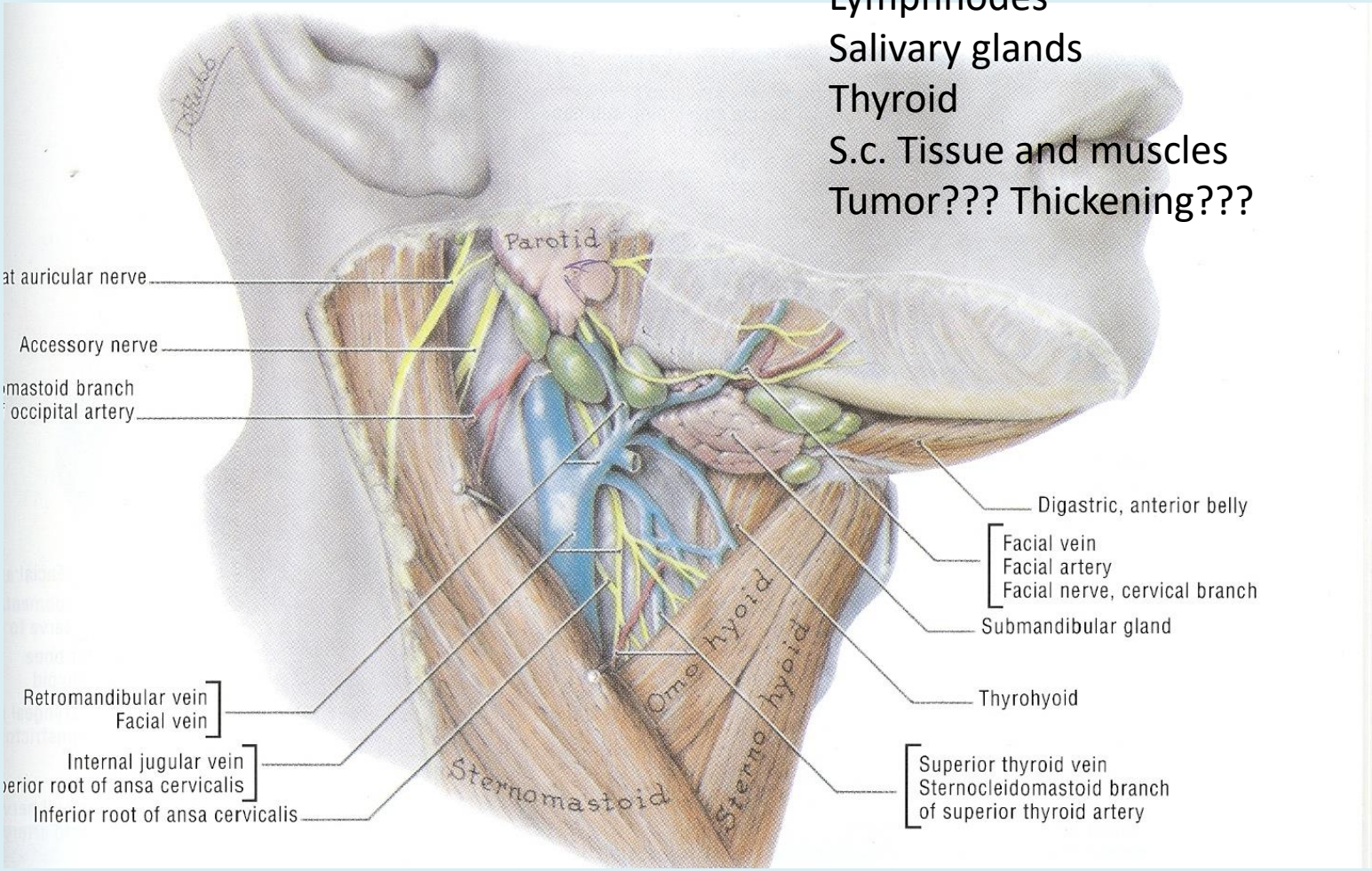

Pathologien

Schwellung Hals (DD):
Lipom, Atherom, Neurinom
Missbildungen: Hygrom, Lymphangiom, Hämangiom
Erkrankungen / Raumforderungen der Speicheldrüsen: Benigne: pleomorphes Adenom, Zystadenolymphom. Maligne: Speicheldrüsenkarzinome. Sialolithiasis
Tumoren der Schilddrüse, maligne /benigne ?
Halszyste (medial, lateral)
Abszess
Jugularvenenthrombose

Vessels
Lymphnodes
Salivary glands
Thyroid
S.c. Tissue and muscles
Tumor??? Thickening???

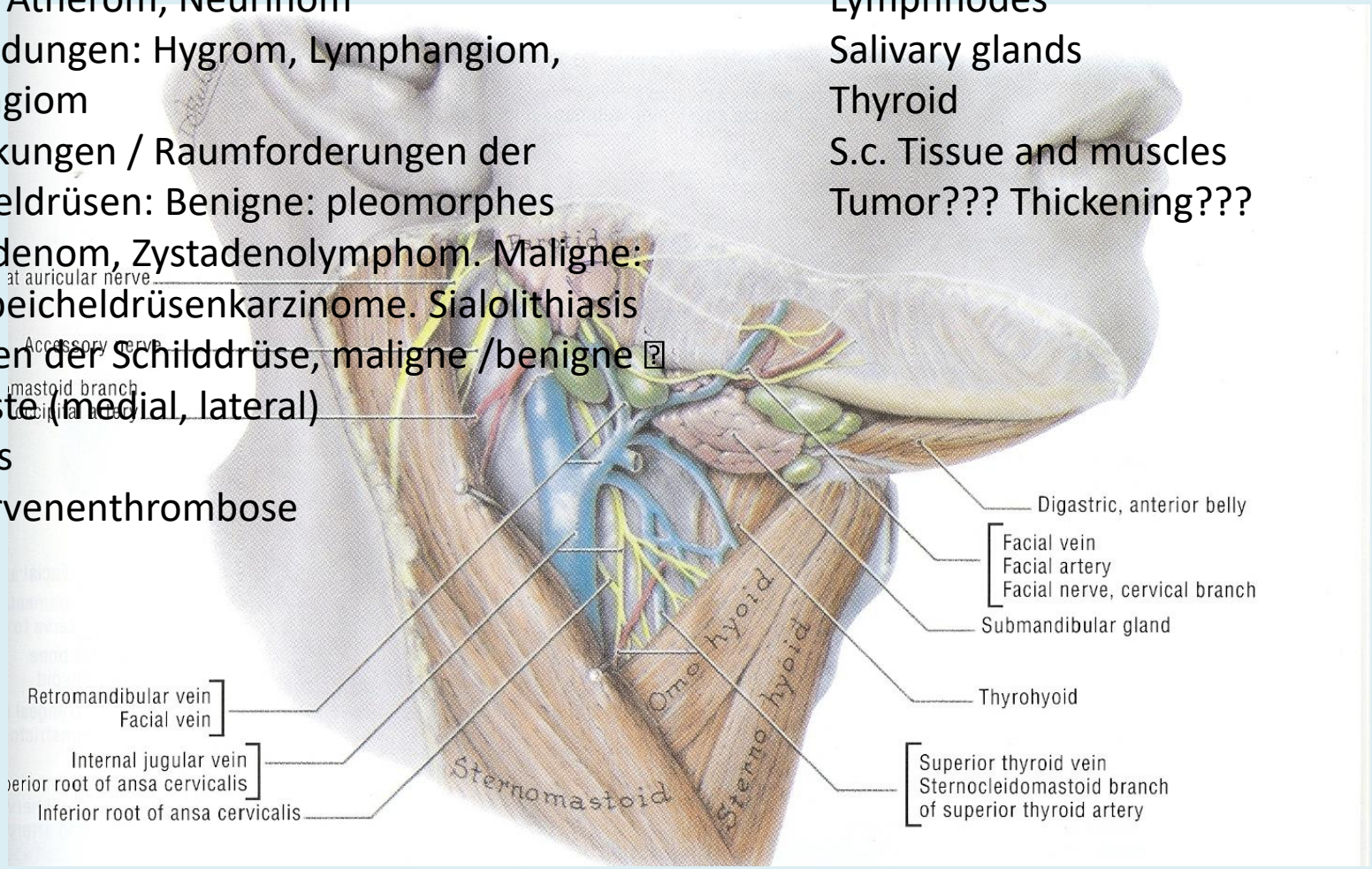

Pathologien

Schwellung Hals (DD):
Lipom, Atherom, Neurinom
Missbildungen: Hygrom, Lymphangiom, Hämangiom
Erkrankungen / Raumforderungen der Speicheldrüsen: Benigne: pleomorphes Adenom, Zystadenolymphom. Maligne: Speicheldrüsenkarzinome. Sialolithiasis
Tumoren der Schilddrüse, maligne /benigne
Halszyste (medial, lateral)
Abszess
Jugularvenenthrombose

Vessels
Lymphnodes
Salivary glands
Thyroid
S.c. Tissue and muscles
Tumor??? Thickening???

Pathologien

Schwellung Hals (DD):
Lipom, Atherom, Neurinom
Missbildungen: Hygrom, Lymphangiom, Hämangiom
Erkrankungen / Raumforderungen der Speicheldrüsen: Benigne: pleomorphes Adenom, Zystadenolymphom. Maligne: Speicheldrüsenkarzinome. Sialolithiasis
Tumoren
Halszyste
Abszess
Jugularv

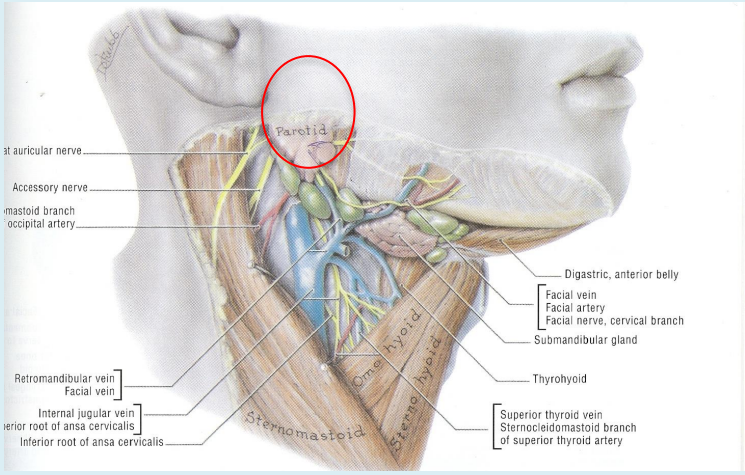

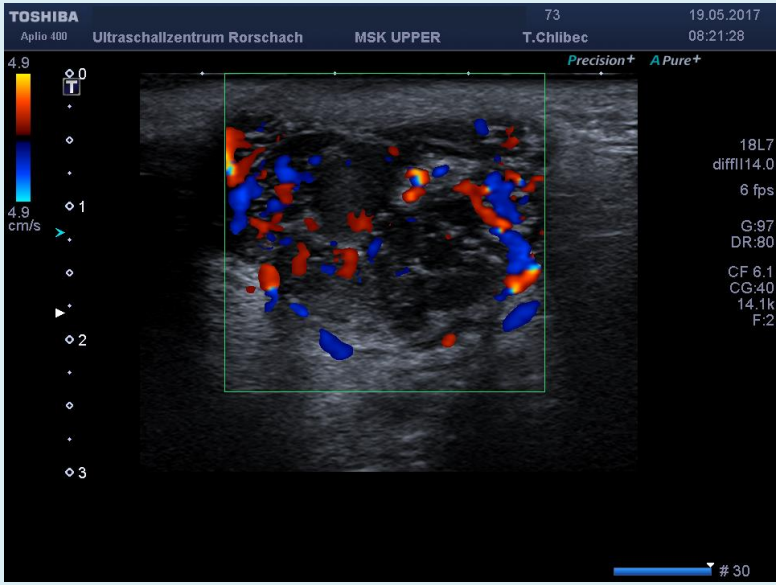

Pathologien

Schwellung Hals (DD):
Lipom, Atherom, Neurinom
Missbildungen: Hygrom, Lymphangiom, Hämangiom
Erkrankungen / Raumforderungen der Speicheldrüsen: Benigne: pleomorphes Adenom, Zystadenolymphom. Maligne: Speicheldrüsenkarzinome. Sialolithiasis
Tumoren der Schilddrüse, maligne /benigne
Halszyste (me
Abszess
Jugularvenent

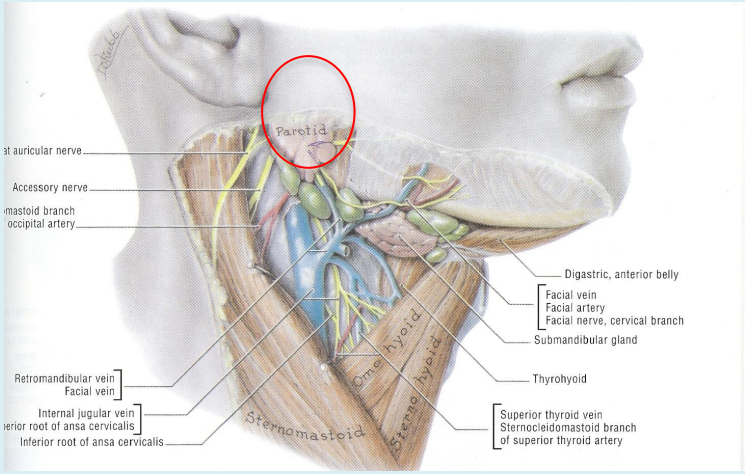

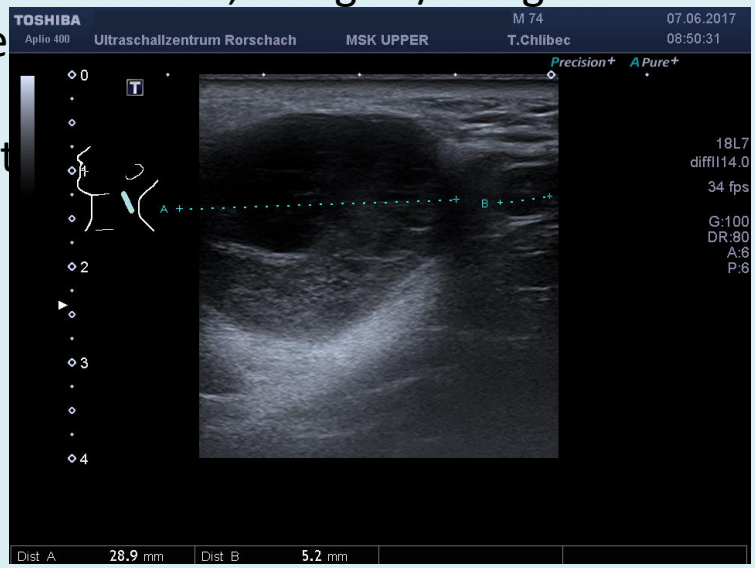

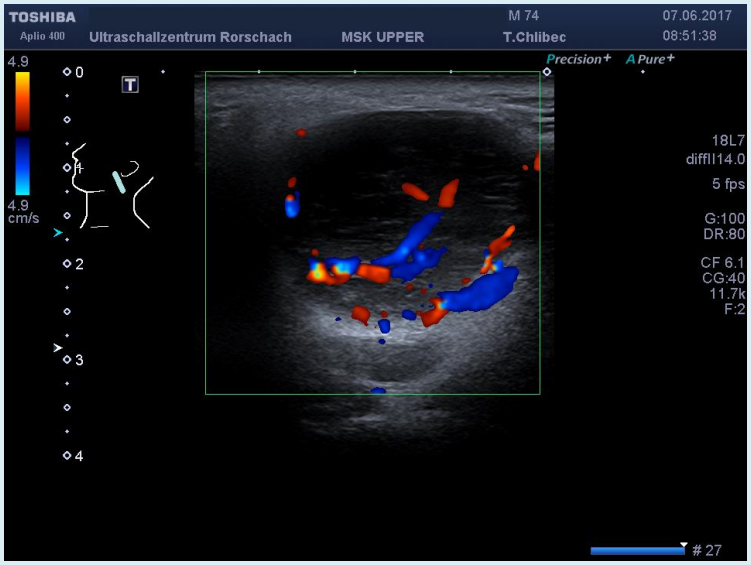

Pathologien

Schwellung Hals (DD):
Lipom, Atherom, Neurinom
Missbildungen: Hygrom, Lymphangiom, Hämangiom
Erkrankungen / Raumforderungen der Speicheldrüsen: Benigne: pleomorphes Adenom, Zystadenolymphom. Maligne: Speicheldrüsenkarzinome. Sialolithiasis
Tumoren der Schilddrüse, maligne /benigne ⍰
Halszyste (medial, lateral)
Abszess
Jugularvenenthrombose

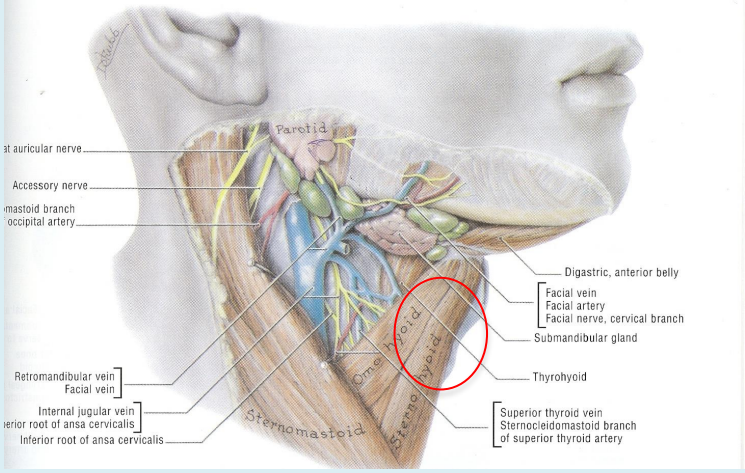

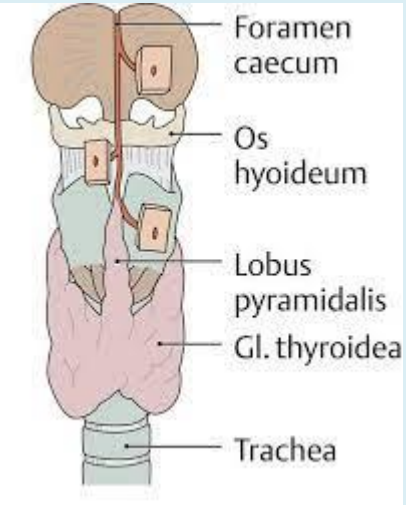

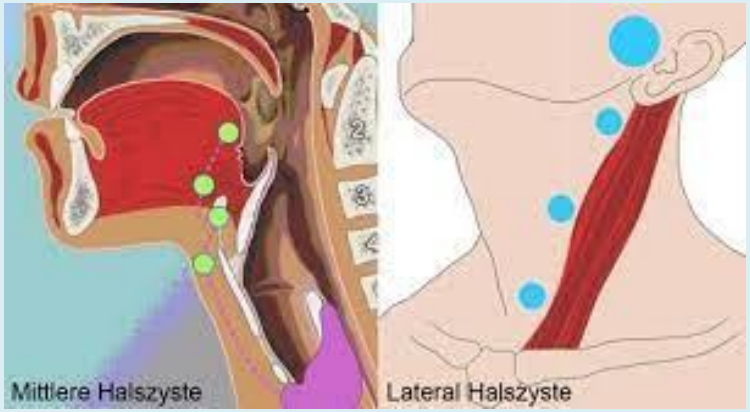

Pathologien

Schwellung Hals (DD):
Lipom, Atherom, Neurinom
Missbildungen: Hygrom, Lymphangiom, Hämangiom
Erkrankungen / Raumforderungen der Speicheldrüsen: Benigne: pleomorphes Adenom, Zystadenolymphom. Maligne: Speicheldrüsenkarzinome. Sialolithiasis
Tumoren der Schilddrüse, maligne /benigne ?
Halszyste (medial, lateral)
Abszess
Jugularvenenthrombose

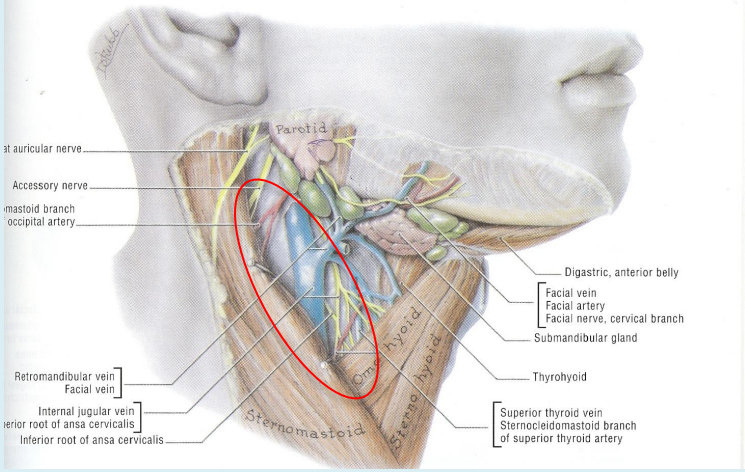

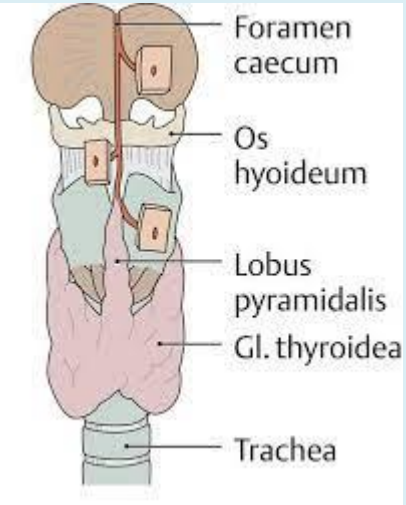

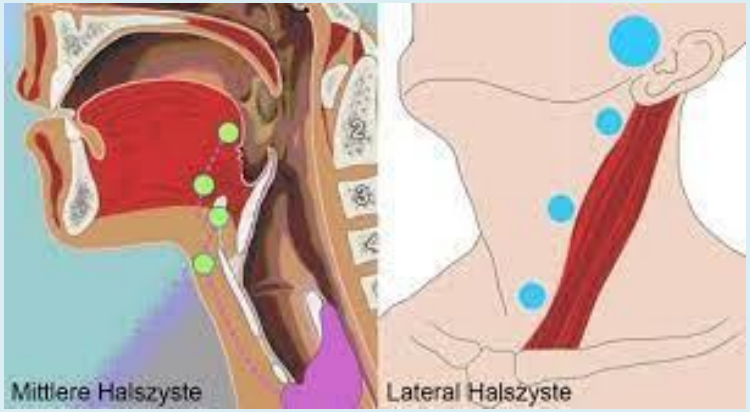

Pathologien, laterale Halszyste

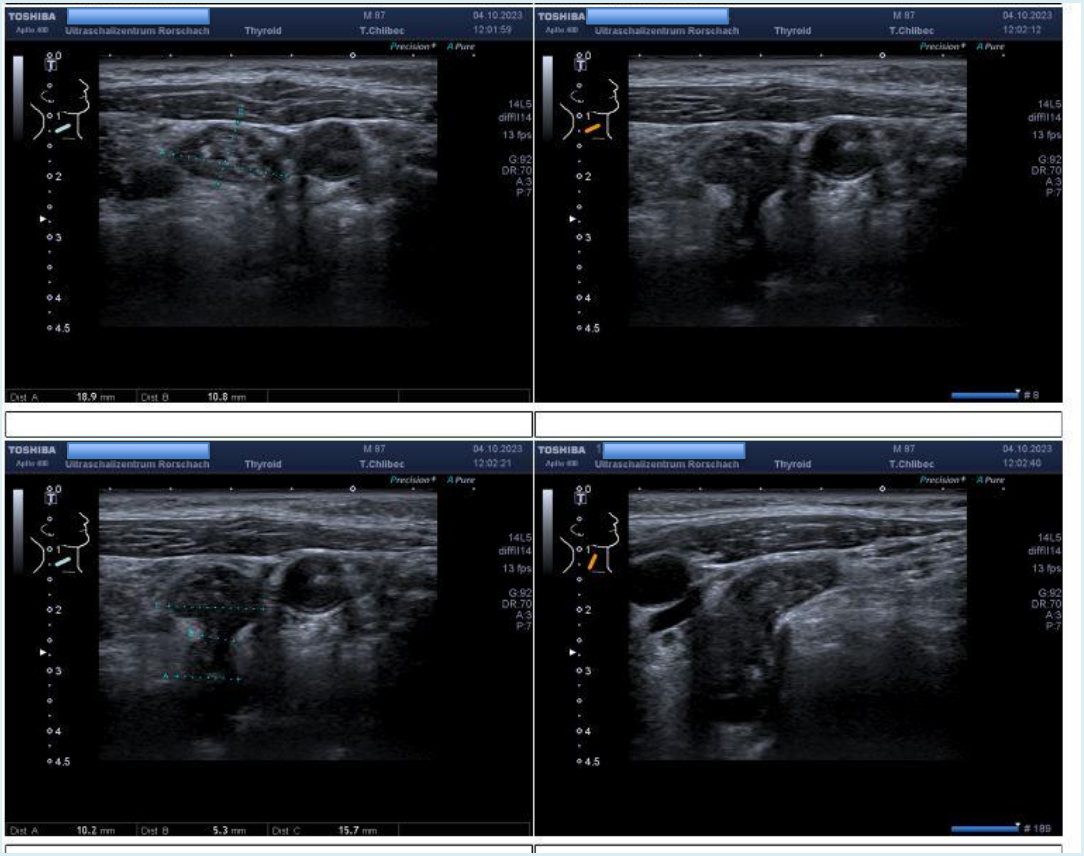

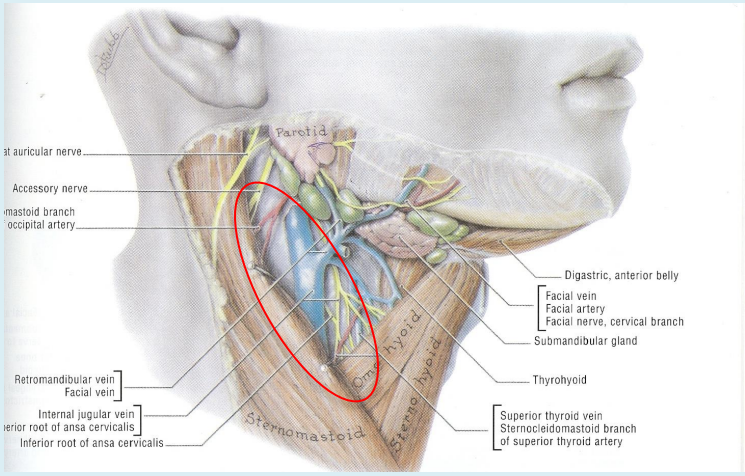

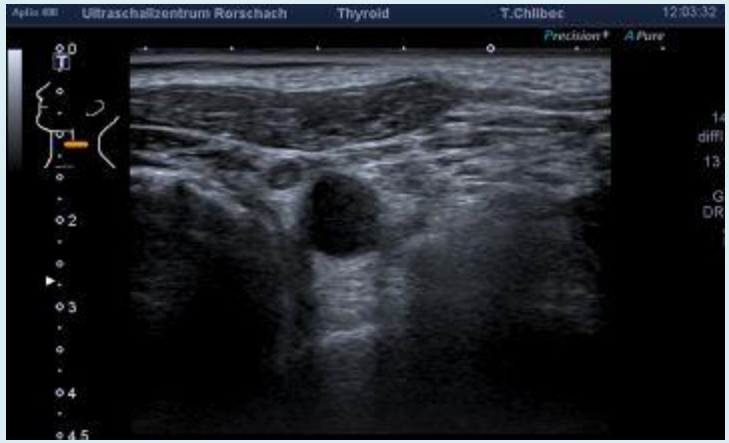

Variante Nebenschilddrüse

Schwellung Hals (DD):
Lipom, Atherom, Neurinom
Missbildungen: Hygrom, Lymphangiom, Hämangiom
Erkrankungen / Raumforderungen der Speicheldrüsen: Benigne: pleomorphes Adenom, Zystadenolymphom. Maligne: Speicheldrüsenkarzinome. Sialolithiasis
Tumoren der Schilddrüse, maligne /benigne.
Halszyste (medial, lateral)
Abszess
Jugularvenenthrombose

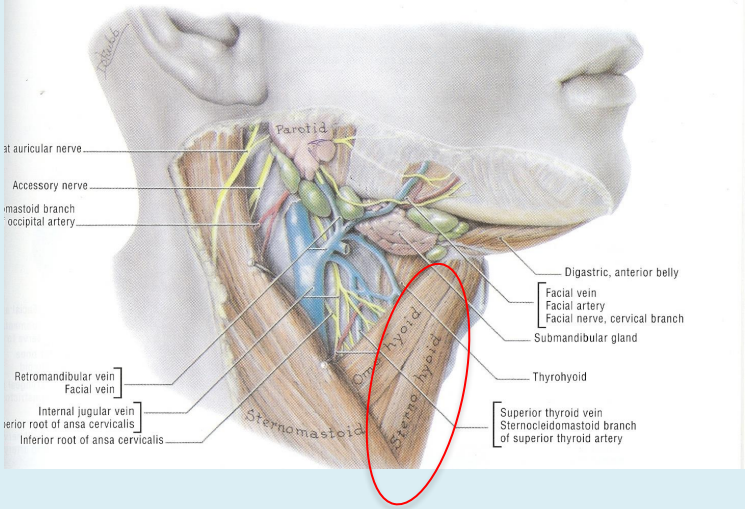

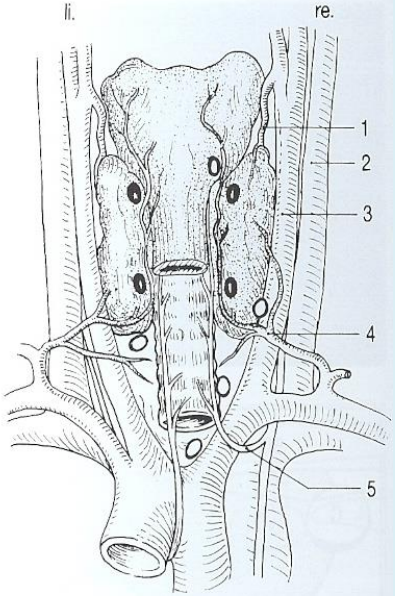

Abb. **17** Topographie der oberen und unteren Epithelkörperchen bei normaler und ektoper Lokalisation. (Sicht von dorsal, offene Kreise: ektope Lokalisation.)
1 = A. thyreoidea superior
2 = V. jugularis interna
3 = A. carotis communis
4 = A. thyreoidea inferior
5 = N. recurrens dexter

Zervikale Lymphknoten

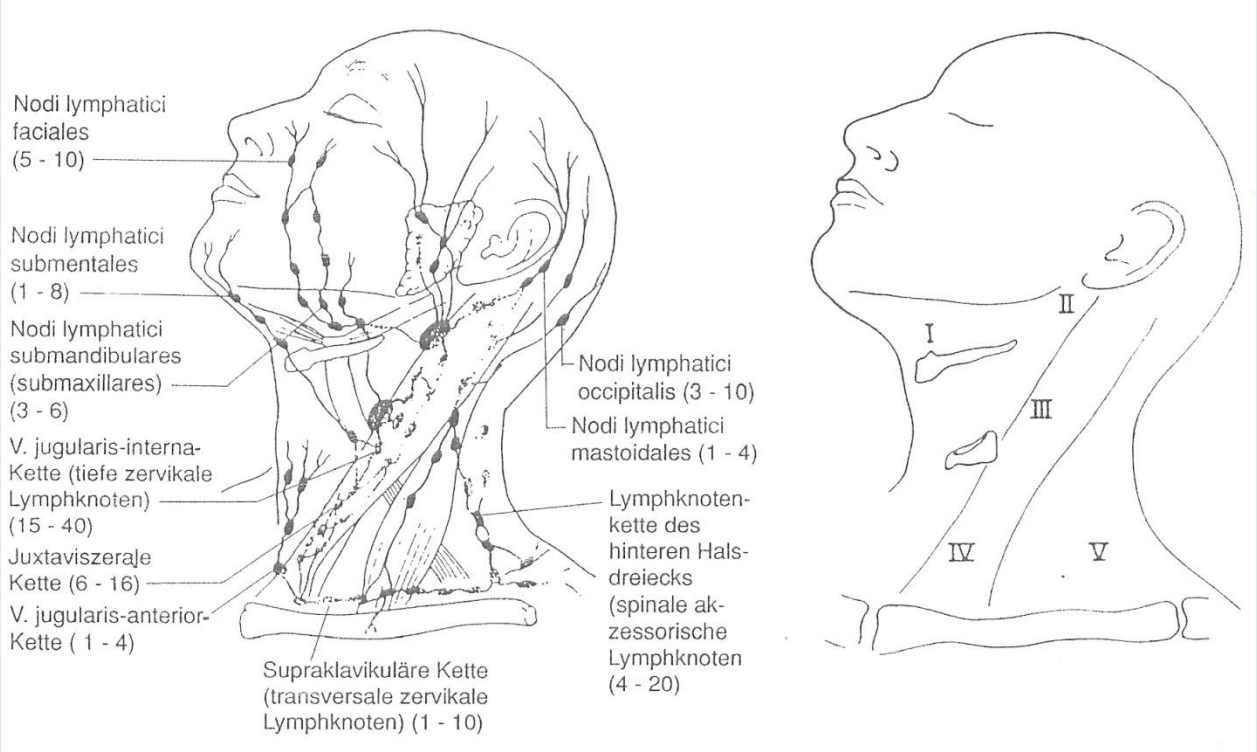

LEVEL

I Trigonum submentale und submandibulare (M.Digastricus, Zungenbein, Mandibula)

II entlang der V. Jugularis cranial

III

IV caudal

V laterales Halsdreieck (Hinterrand m.sternocleidomastoideus, Vorderrand M.Trapezius)

VI ventrals Halsdreieck (Zungenbein, Mohrenheimsche Grube, M. Sternocleidomastoideus)

Zervikale Lymphknoten

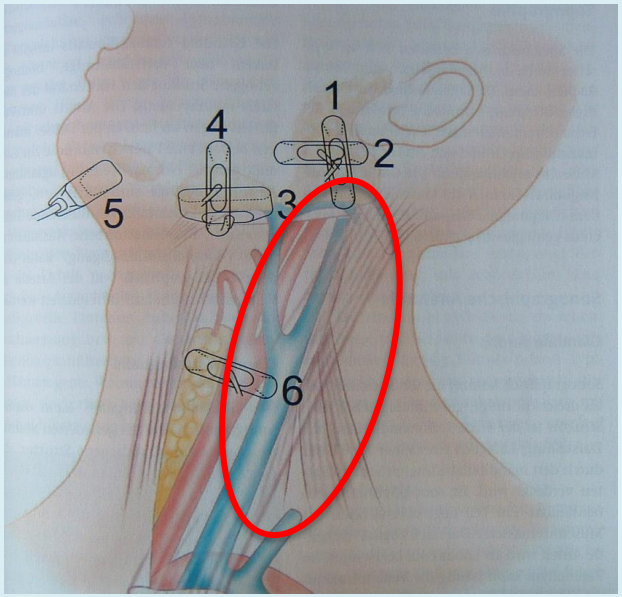

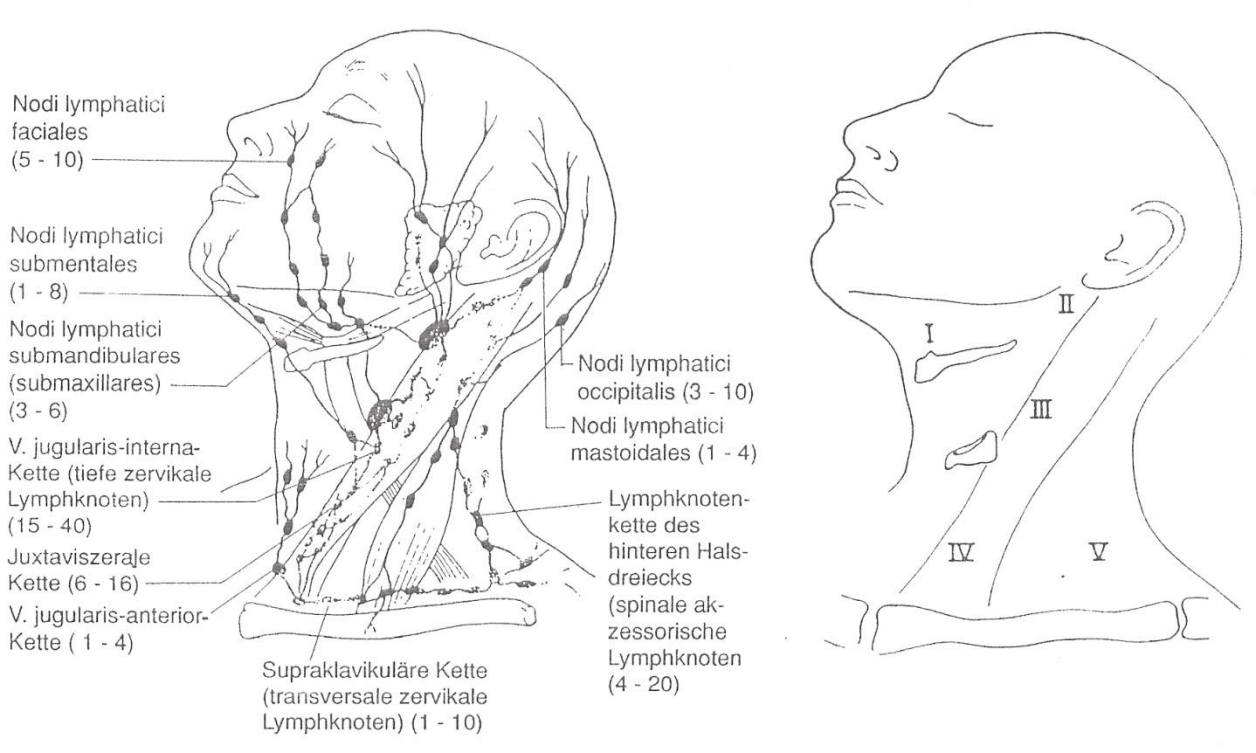

Zervikale Lymphknoten

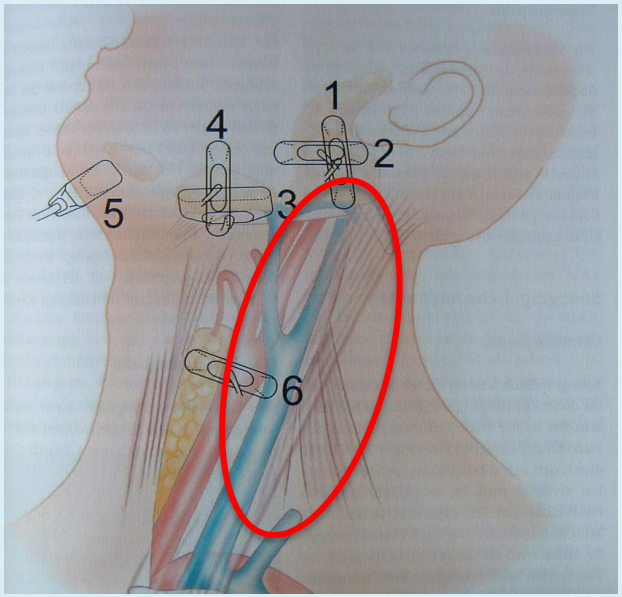

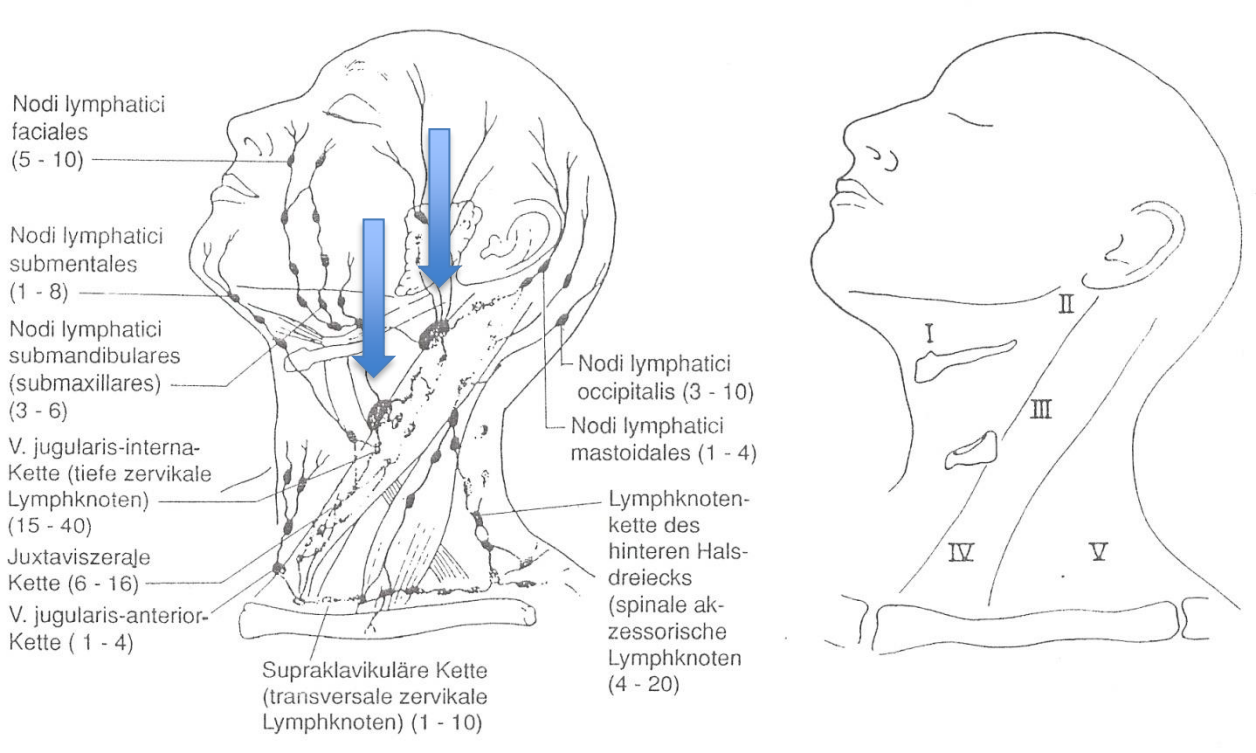

Sonoanatomie li Halsseite

Normalbefund

Normalbefund

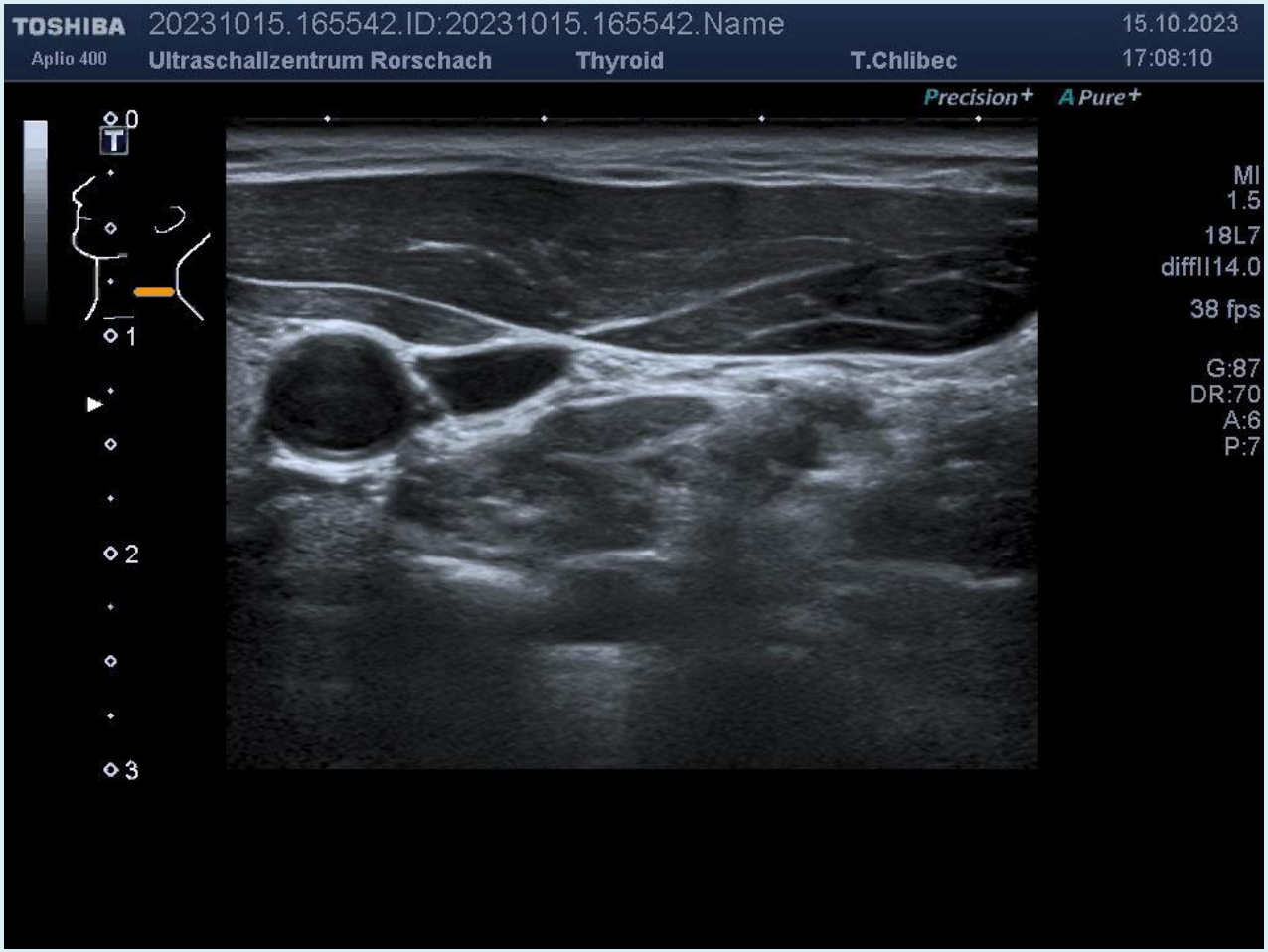

Mögliche Ursachen der Lymphknotenpathologien

- Unspezifisch: viral, bakteriell (tonsillogen, dentogen) = Häufigste Ursache cervikal!
- Spezifisch: Mononukleose, Toxoplasmose, Zytomegalie, Lues, HIV, Tuberkulose, Katzenkratzkrankheit
- Lymphknotenmetastase Plattenepithelkarzinome
- Lymphom

Zervikale Lymphknoten

<u>Sonografische Beurteilungskriterien (Criterias):</u>

- Grösse Size
- Form / Maximal-Querdurchmesser-Quotient (>2)
- Zentraler Hilusreflex
- Echogenität
- Begrenzung Margin

Sonografische Beurteilungskriterien

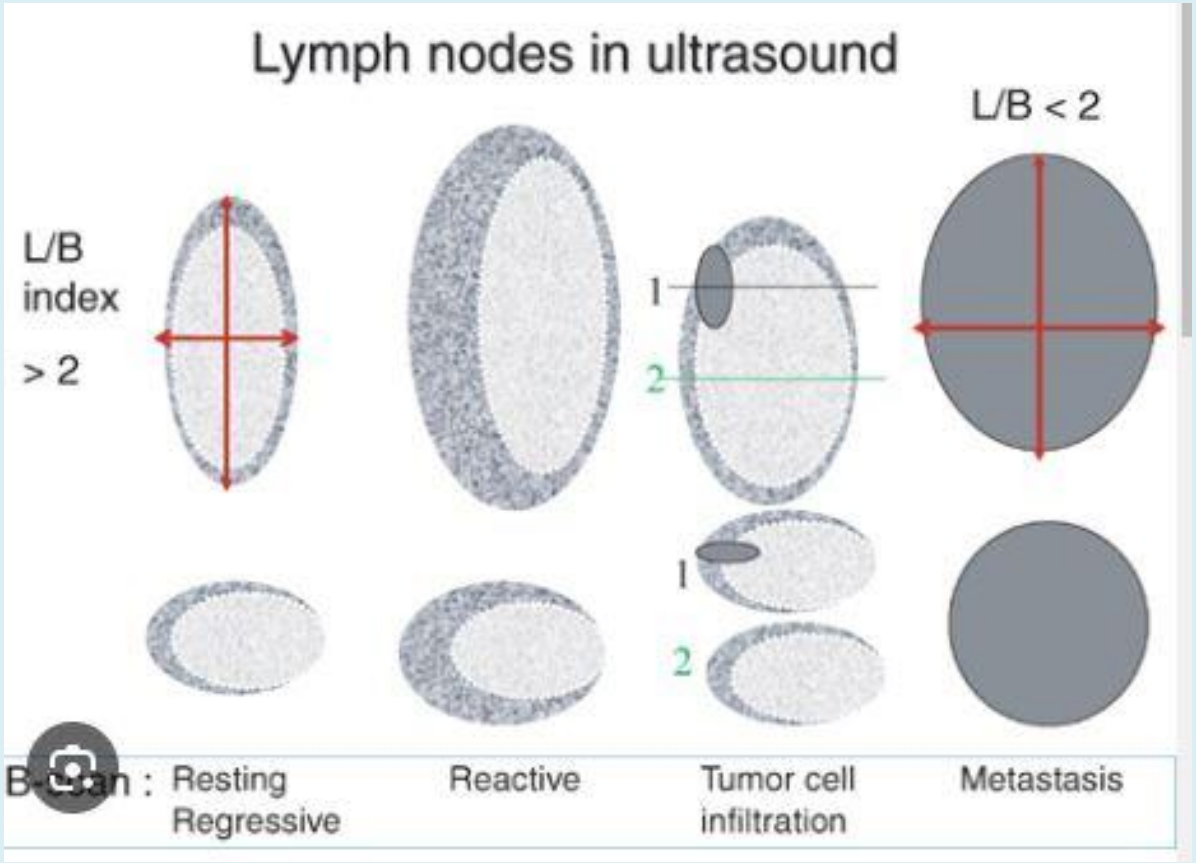

Wiley Online Library

Normale cervikale Lymphknoten

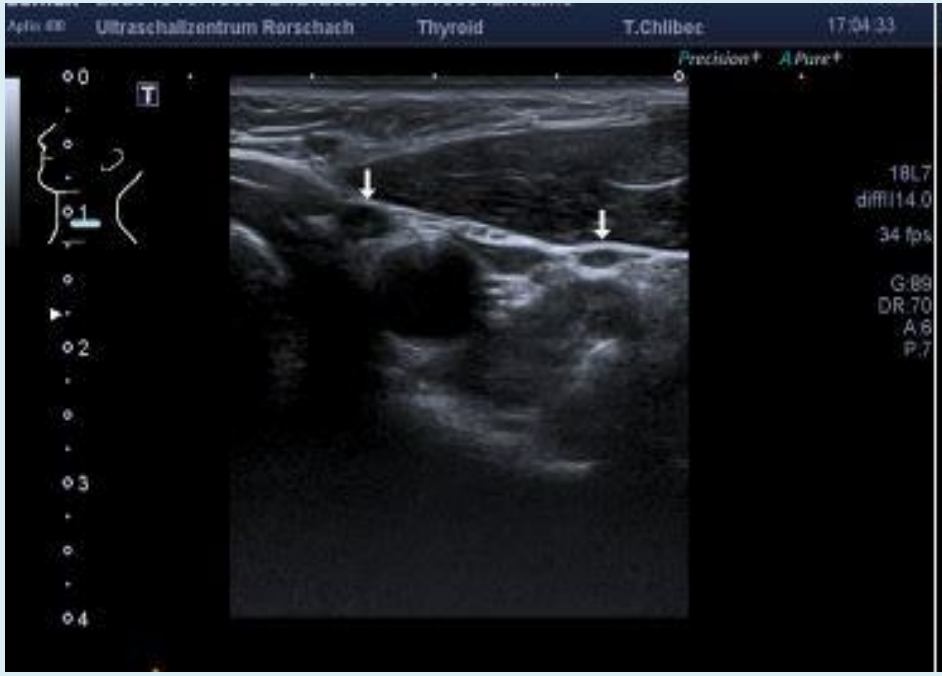

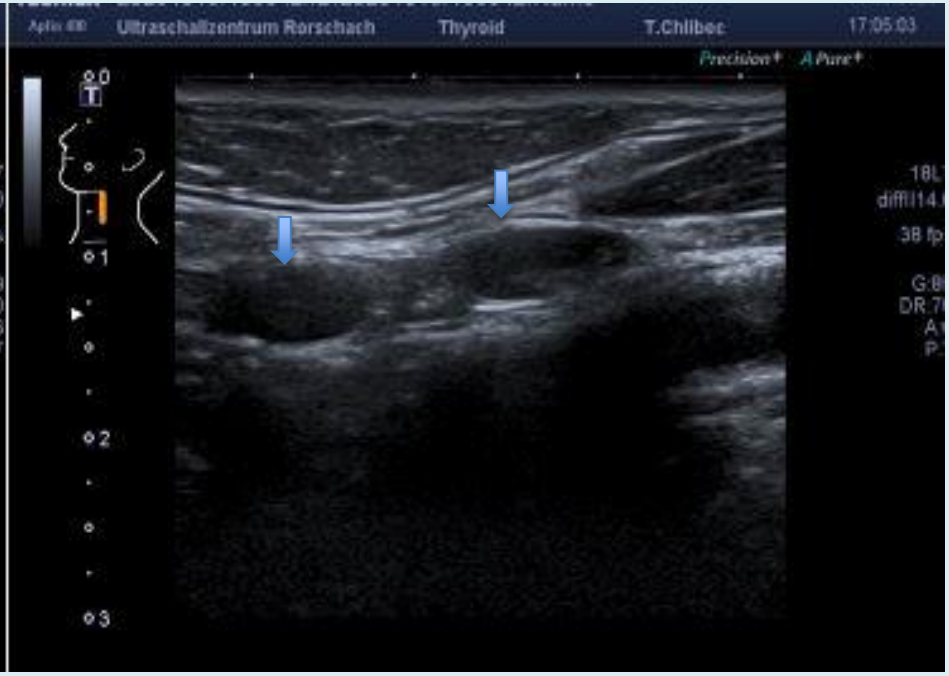

Normale cervikale Lymphknoten

Zervikale Lymphknoten

Reaktiver LKN

Zervikale Lymphknoten

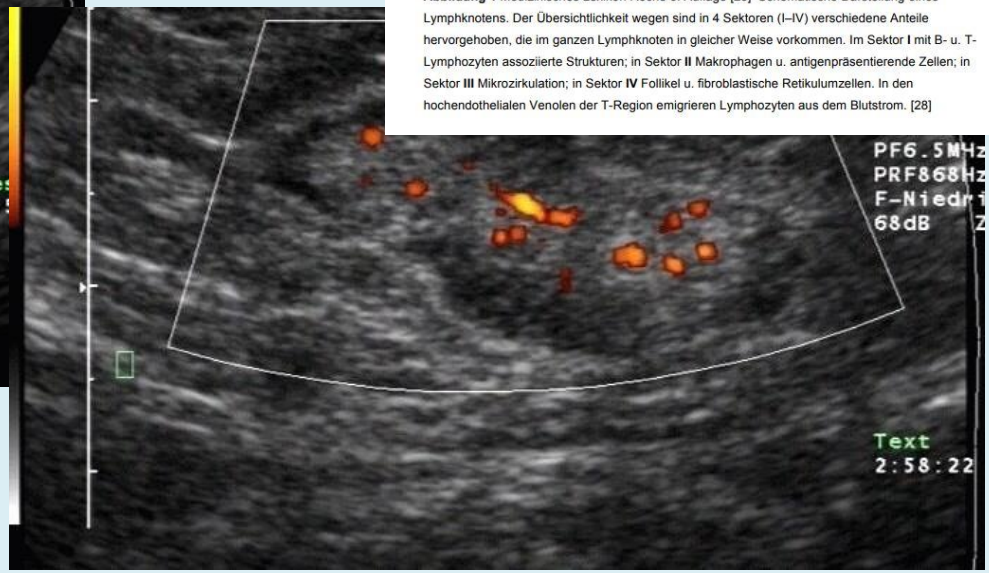

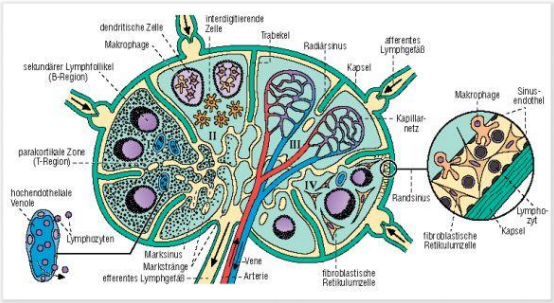

Abbildung 1 Medizinisches Lexikon Roche 5. Auflage [28] Schematische Darstellung eines Lymphknotens. Der Übersichtlichkeit wegen sind in 4 Sektoren (I–IV) verschiedene Anteile hervorgehoben, die im ganzen Lymphknoten in gleicher Weise vorkommen. Im Sektor **I** mit B- u. T-Lymphozyten assoziierte Strukturen; in Sektor **II** Makrophagen u. antigenpräsentierende Zellen; in Sektor **III** Mikrozirkulation; in Sektor **IV** Follikel u. fibroblastische Retikulumzellen. In den hochendothelialen Venolen der T-Region emigrieren Lymphozyten aus dem Blutstrom. [28]

Reaktiver LKN

Zervikale Lymphknoten

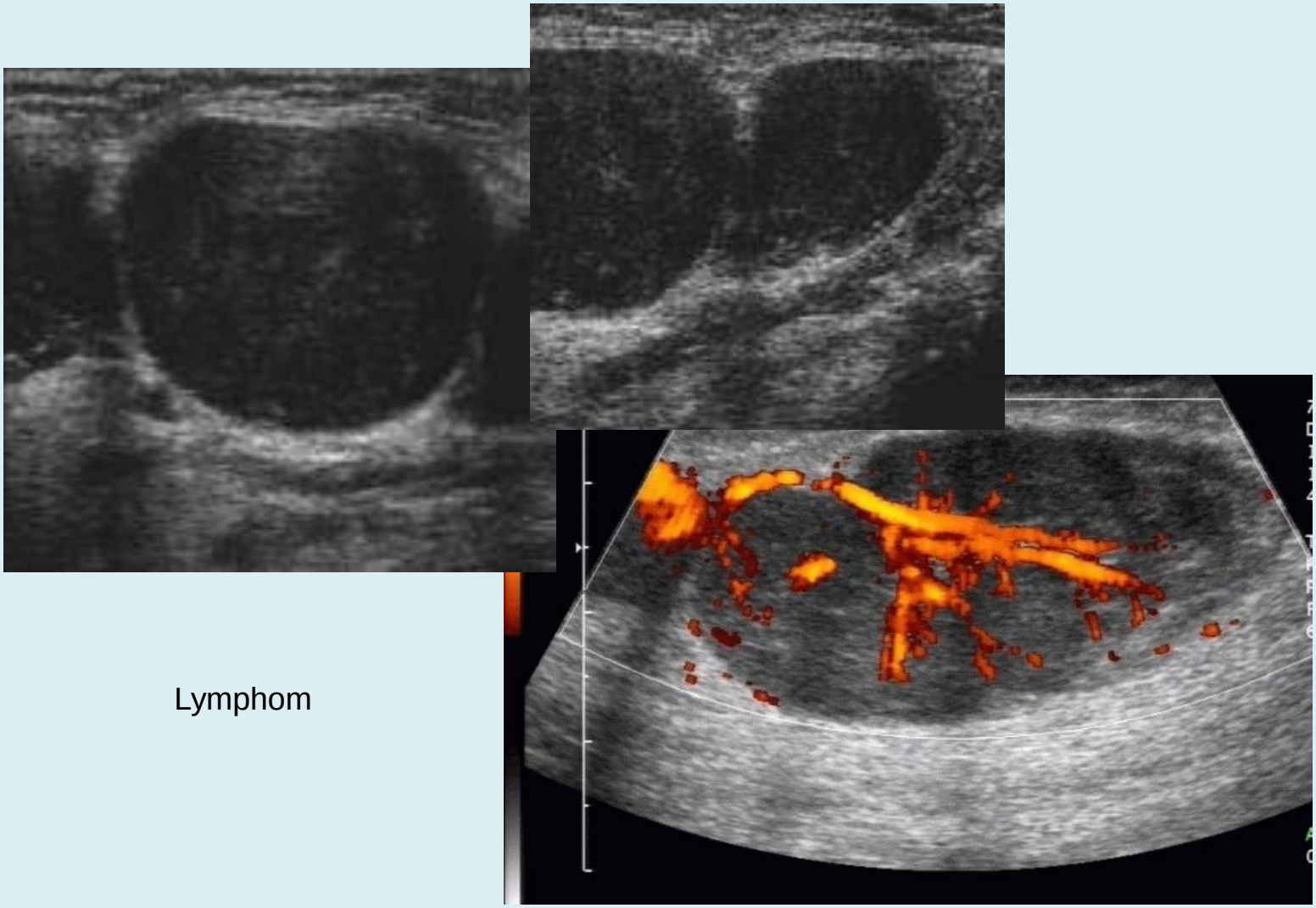

Lymphom

Zervikale Lymphknoten

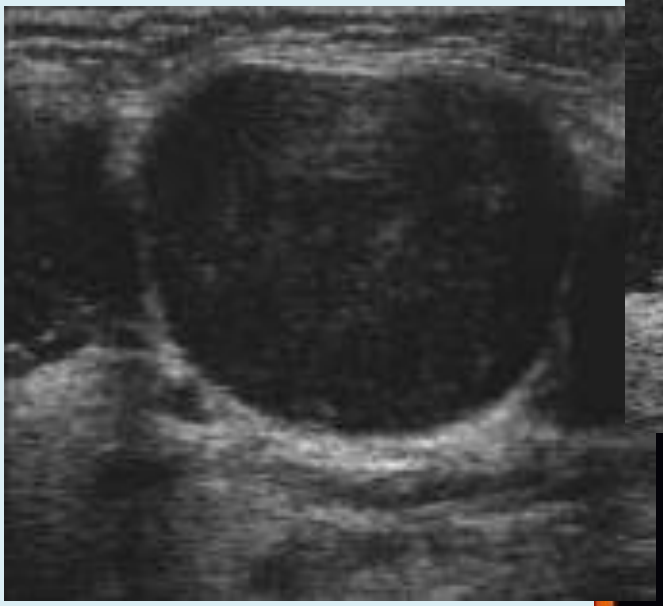

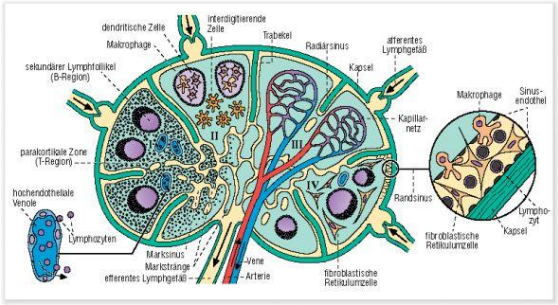

Abbildung 1 Medizinisches Lexikon Roche 5. Auflage [28] Schematische Darstellung eines Lymphknotens. Der Übersichtlichkeit wegen sind in 4 Sektoren (I–IV) verschiedene Anteile hervorgehoben, die im ganzen Lymphknoten in gleicher Weise vorkommen. Im Sektor **I** mit B- u. T-Lymphozyten assoziierte Strukturen; in Sektor **II** Makrophagen u. antigenpräsentierende Zellen; in Sektor **III** Mikrozirkulation; in Sektor **IV** Follikel u. fibroblastische Retikulumzellen. In den hochendothelialen Venolen der T-Region emigrieren Lymphozyten aus dem Blutstrom. [28]

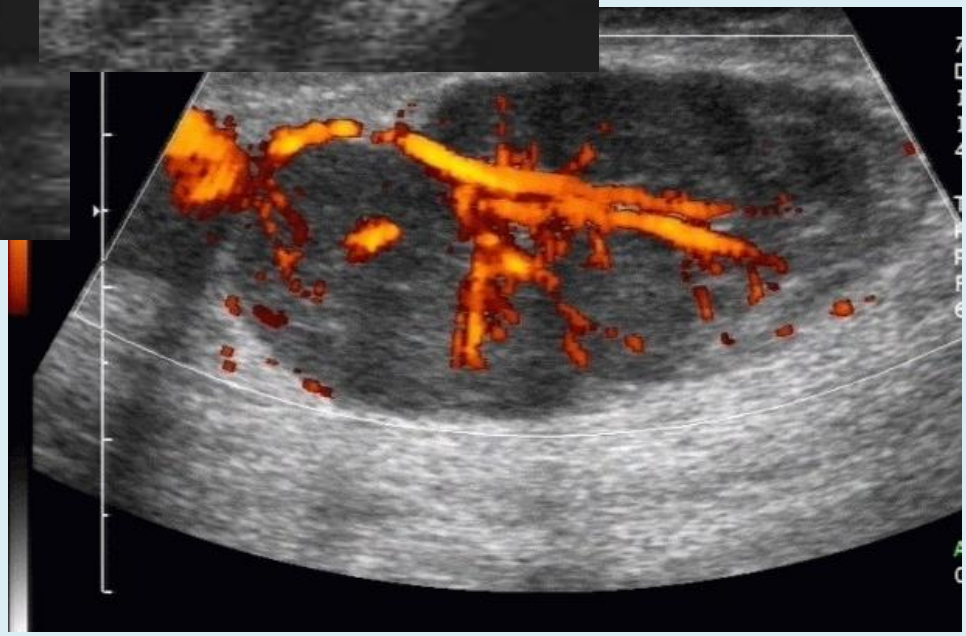

Lymphom

Sonografische Beurteilungskriterien

Physiologische Lymphknoten:	vs	Malignes Lymphom:
•Kleiner 1,5 cm		•Meist kugelige Form (MQQ<2)
•Längliche Form (MQQ>2)		•Echoarm (insbesondere Kortex)
•Echoreicher „verfetteter“ Hilus		•Fehlender Hilusreflex (50-80%)
•Scharfe Begrenzung		•Scharfe Begrenzung
•Duplex: Vascularisation fehlt oder nur am Hilus		•Hypervaskularisation (ev. Baum- oder Radspeichenmuster)

Sonstiges:

•Lymphadenitis: längsovale Form (akute vs chronisch: Vaskularisation)

•Metastase: unscharfe Begrenzung
Kortex komplex
Duplex: erhöhter RI (>0,8)

Zervikale Lymphknoten, weitere Pathologien

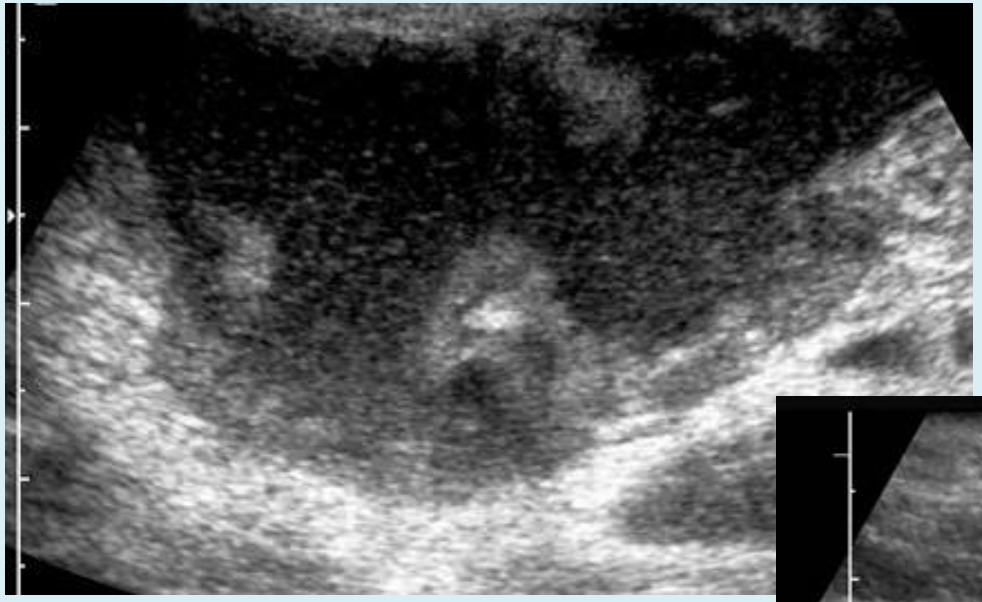

TB

Zervikale Lymphknoten, weitere Info

- Oberflächliche Lage von cervikalen LKN: hochfrequenter Schallkopf (5-10 MHz)
- Cervikale Lymphknotenmetastasen sind bei Kopf-Hals Tumoren ein entscheidender prognostischer Faktor
- Thorakale Tumoren können in zervikale LKN metastasieren
- Staging bei Malignen Lymphomen (MH, NHL. 60-80% aller Maligner Lymphome)
- Metastasen: 1/3 aller persistierenden Hals-LKN-Schwellungen
  Davon 85% regionale von Kopf-Hals-Tu (einschl. SD)
  10% Fernmetastasen Lunge, MDT, Mama, Urogenital
  5% CUP

Lymphknoten, weitere Info

AWMF 025_020 **April 2020**

Abb. 3: Nicht zervikale Lymphknotengruppen und Drainagewege (

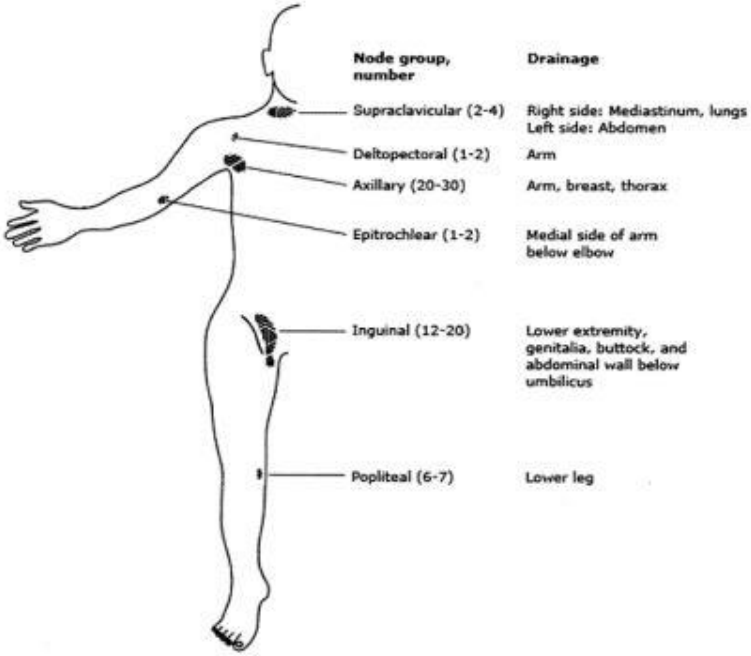

Ferrer RL. Evaluation of peripheral lymphadenopathy in adults. In: UpToDate, Post TW (Hrsg), UpToDate, Waltham, MA, USA. Copyright ©2020 UpToDate, Inc. Für weitere Informationen s.a. www.uptodate.com

Fragen?

I WAS READING ABOUT HOW COUNTLESS SPECIES ARE BEING PUSHED TOWARD EXTINCTION BY MAN'S DESTRUCTION OF FORESTS.
©1989 Universal Press Syndicate
SOMETIMES I THINK THE SUREST SIGN THAT INTELLIGENT LIFE EXISTS ELSEWHERE IN THE UNIVERSE IS THAT NONE OF IT HAS TRIED TO CONTACT US.

Outtakes

Carotis

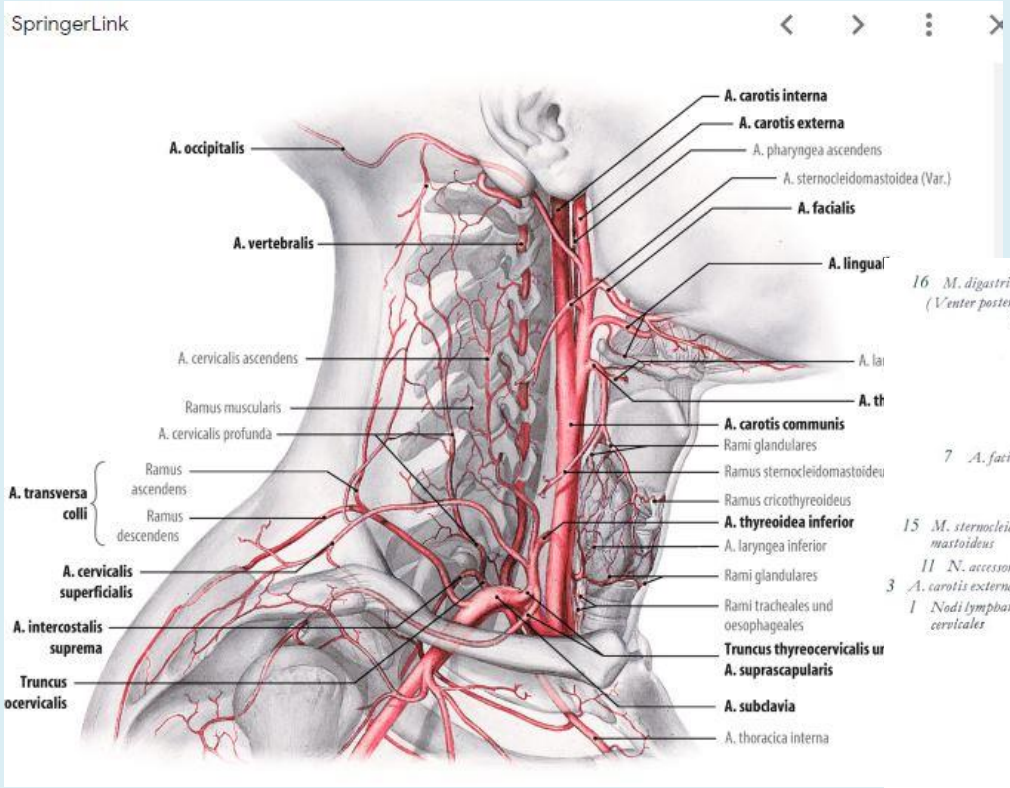
SpringerLink
A. occipitalis
A. vertebralis
A. cervicalis ascendens
Ramus muscularis
A. cervicalis profunda
A. transversa colli
Ramus ascendens
Ramus descendens
A. cervicalis superficialis
A. intercostalis suprema
Truncus ocervicalis
A. carotis interna
A. carotis externa
A. pharyngea ascendens
A. sternocleidomastoidea (Var.)
A. facialis
A. lingual
A. carotis communis
Rami glandulares
Ramus sternocleidomastoideu
Ramus cricothyreoideus
A. thyreoidea inferior
A. laryngea inferior
Rami glandulares
Rami tracheales und oesophageales
Truncus thyreocervicalis ur
A. suprascapularis
A. subclavia
A. thoracica interna

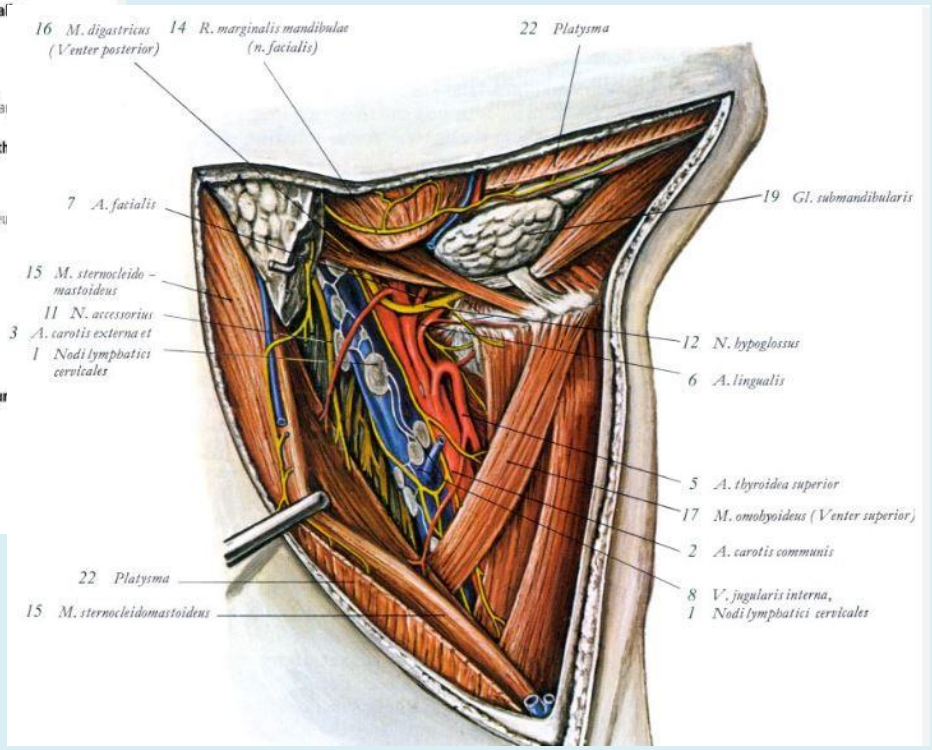
16 M. digastricus (Venter posterior)
14 R. marginalis mandibulae (n. facialis)
22 Platysma
7 A. facialis
19 Gl. submandibularis
15 M. sternocleido-mastoideus
11 N. accessorius
3 A. carotis externa et
1 Nodi lymphatici cervicales
12 N. hypoglossus
6 A. lingualis
5 A. thyroidea superior
17 M. omohyoideus (Venter superior)
2 A. carotis communis
8 V. jugularis interna,
1 Nodi lymphatici cervicales
22 Platysma
15 M. sternocleidomastoideus

1

Canada Lymph Node Score

Ultrasonographic Features	Benign Features (0 points)	Malignant Features (1 point)
Margins		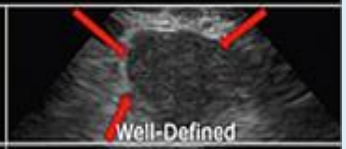
Central Hilar Structure		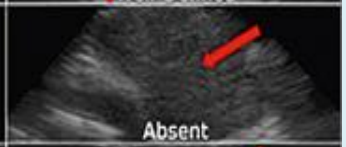
Central Necrosis		
Small Axis Diameter	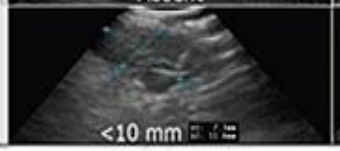	

Scores: 0-1 = Low chance of malignancy | 2-4 = High chance of malignancy